NOR-CAL EMS	05-0920	Skills: Skills: 12 Lead EKG

Nor-Cal EMS Policy & Procedure Manual	BLS/ALS Protocols
Effective Date: 10/01/2020	Next Revision: 10/01/2023
Approval: Jeffrey Kepple MD – MEDICAL DIRECTOR	SIGNATURE ON FILE

Authority: Health and Safety Code Division 2.5, California Code of Regulations, Title 22, Division 9.

Provider Name: Provider's Signature:	Cert #: Provider Agency:
Validator's Name: Validator's Signature:	Date:

PERFORMANCE CRITERIA	MET (Initials)	NOT MET (Initials)	COMMENTS
1. Do not delay assessment and treatment. Follow appropriate policies regarding the patient's clinical assessment, i.e. Chest Pain protocol.			
2. Explain to the patient the procedure and the importance of obtaining an EKG.			
3. Expose the chest and prepare the patient's skin for electrode placement. Dry the skin if it is excessively moist. If there is significant chest hair, use a razor to shave areas where leads will be placed.			
4. EKGs on female patients: A. Be sensitive when exposing or touching the breast. B. Always place the V3-V6 leads under the breast, rather than on the breast. C. Always use the back of your hand when displacing the breast.			
5. Attach EKG leads to the patient: A. Place the electrodes on the limbs. The limb leads can be placed anywhere from the shoulders to the wrist and the thighs to the ankles – NOT the torso. B. Place the electrodes on the chest. The six precordial (chest) lead electrodes: **STANDARD EKG LEAD PLACEMENT** **V1**: right 4th intercostal space, right sternal border **V2**: left 4th intercostal space, left sternal border **V3**: Halfway between V2 and V4 on a diagonal line **V4**: 5th intercostal space, left midclavicular line **V5**: left anterior axillary line, same horizontal line as V4 and V6 **V6**: left mid-axillary line, same horizontal line as V5 and V6			
6. States when R side EKG is REQUIRED			

7. RIGHT SIDED EKG LEAD PLACEMENT Limb leads remain unchanged from the standard EKG lead placement **V1R 4th intercostal space, left sternal border V2R 4th intercostal space, right sternal border** **V3R halfway between V2R and V4R, on a diagonal line** **V4R 5th intercostal space, right midclavicular line** **V5R right anterior axillary line, same horizontal line as V4R and V6R** **V6R right mid-axillary line, same horizontal line as V5R and V6R** **Verbalizes indications for performing a right sided EKG**			
8. Encourage the patient to remain as still as possible and not to talk, run the 12- lead EKG			
9. If the 12-Lead EKG shows ST elevation in 2 or more contiguous leads, the 12 lead self-diagnoses an acute MI, or at the paramedics' discretion transmit the EKG to the receiving facility.			
10. Upon making BHC with the receiving facility include interpretation of ST elevation, involved leads, and millimeters of elevation.			
11. Documentation: A copy of the 12 lead EKG shall be attached to the PCR. If a right sided EKG the copy **MUST** be labeled right sided EKG			

INDICATIONS FOR A RIGHT SIDED 12 LEAD EKG
(Used to detect a right ventricular STEMI associated with occlusion of the right coronary artery)

1. ST elevation in the inferior leads, II, III, and aVF. (ST elevation that is greatest in lead III is especially significant)
2. ST elevation in V1 (considered to be the only precordial lead that faces the RV on the standard 12 lead EKG)
3. Other findings may include: right bundle branch block, second- and third- degree atrioventricular blocks. Hypotension with clear lung fields.

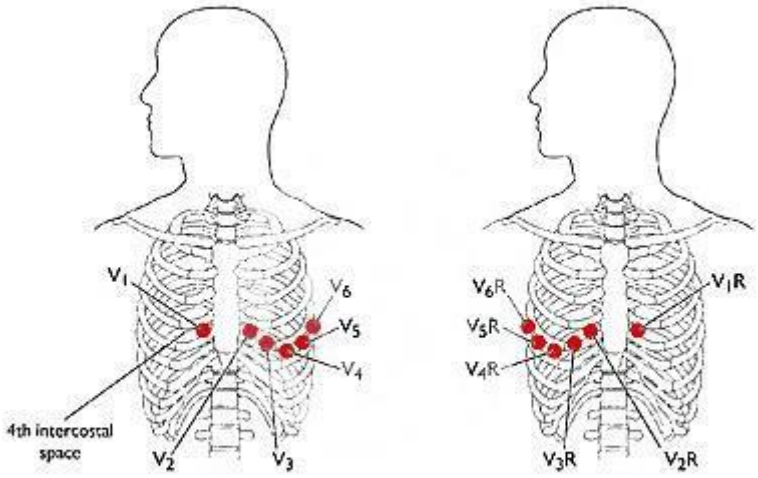

A. Standard chest lead placement

B. Right sided chest lead placement